

Evaluation of Low Grade Bacterial Infection of the Intervertebral Disc

Thomas Fisher

Centre for Orthopaedic & Trauma Research

School of Medicine

Faculty of Health Sciences

University of Adelaide

October 2015

Table of Contents

Abstract.....	3
Author Declaration.....	5
Introduction.....	6
Chapter 1	8
Literature Review – Do Bacteria Play an Important Role in the Pathogenesis of Low Back Pain?.....	9
Chapter 2.....	16
Modic Changes: Do They Predict Growth of Propionibacterium Acnes in Intervertebral Disc Material?	17
Chapter 3.....	36
Modic Changes and Surgical Outcomes	38
Discussion.....	49
References.....	51
Acknowledgements.....	53

Abstract

This thesis considers the novel concept that persistent low back pain in the setting of intervertebral disc herniation and specific signal changes on magnetic resonance imaging (MRI) may reflect a previously unrecognised low grade anaerobic bacterial infection, specifically with *Propionibacterium Acnes* (*P. Acnes*). A prolonged course of oral antibiotics has been proposed as an effective treatment strategy in patients with such an infection. This hypothesis has the potential to dramatically alter the approach to treatment of these patients in whom traditionally surgery may have been offered.

A comprehensive review of the literature was performed initially, showing a wide variation in the rate of bacterial growth from intervertebral discs sampled during open surgery. While many papers commented on their adherence to strict sterility procedures during collection of specimens, details on these procedures was scant and therefore comparison between findings was difficult.

The primary experiment in this project was the collection of intervertebral disc samples from patients undergoing open spinal surgery with a view to histopathological review, bacterial culture and polymerase chain reaction for *P. Acnes*. The results of these cultures were compared against pre-operative MRI findings, in particular the presence of Modic changes at the vertebral endplates corresponding to level of surgery. This study found no relationship between the presence of Modic changes and subsequent identification of bacteria in discs.

A secondary experiment was conducted to consider an extrapolation of this hypothesis. If infection was the source of ongoing pain, then without adequately addressing the primary pathology a poor outcome would be expected. It was therefore proposed that if low grade bacterial infection was the source of some patients' persistent pain, it should follow that

surgical outcomes would be poorer in this group than those without infection. Presence of Modic changes at operative levels was used as a surrogate marker for potential bacterial infection and patients were contacted approximately two years after their procedure. No significant difference was found in outcomes between the two groups.

The findings of these experiments call into question the claims made about the ability of a clinician to successfully treat chronic low back pain with oral antibiotics. It is proposed that contamination of the surgical field is the source of bacterial growth in specimens excised for culture. It is difficult to definitively refute the hypothesis that clinically important – but low grade – infection contributes to pain in some patients. Without strong evidence of either the existence of such infections, or a reliable non-invasive method of diagnosis, the proposed antibiotic treatment strategy cannot be supported.

Author Declaration

I certify that this work contains no material which has been accepted for the award of any other degree or diploma in my name, in any university or other tertiary institution and, to the best of my knowledge and belief, contains no material previously published or written by another person, except where due reference has been made in the text. In addition, I certify that no part of this work will, in the future, be used in a submission in my name, for any other degree or diploma in any university or other tertiary institution without the prior approval of the University of Adelaide and where applicable, any partner institution responsible for the joint-award of this degree. I give consent to this copy of my thesis when deposited in the University Library, being made available for loan and photocopying, subject to the provisions of the Copyright Act 1968. The author acknowledges that copyright of published works contained within this thesis resides with the copyright holder(s) of those works. I also give permission for the digital version of my thesis to be made available on the web, via the University's digital research repository, the Library Search and also through web search engines, unless permission has been granted by the University to restrict access for a period of time.

Thomas Fisher

29th October 2015

Introduction

Chronic low back pain is a prevalent problem worldwide which contributes significantly to healthcare costs, loss of productivity and development of comorbid depression and anxiety¹. It is also a feature of many compensation claims relating to injuries sustained in workplace and traffic accidents.

While most patients with herniation of an intervertebral disc improve through a combination of gentle mobilisation, physiotherapy and appropriate analgesia, a proportion of patients do not. For those patients in whom leg pain is also a prominent feature, surgical intervention can play a role in resection of the offending herniation of intervertebral disc. Several mechanisms are thought to contribute to pain associated with intervertebral disc herniation including direct, mechanical pressure on nerve roots, the irritating nature of the relatively toxic contents of the nucleus pulposus, and an inflammatory response to these contents which are normally not exposed²⁻⁵.

A novel hypothesis has emerged however that *P. Acnes*, a commensal organism of the skin and mouth, can enter the herniated disc during periods of transient bacteraemia⁶. Due to the relatively hostile and avascular environment of the disc, the body's immune system does not sufficiently clear this infection, and therefore pain does not resolve.

This thesis begins by reviewing the literature to examine what evidence exists for this hypothesis, and whether other authors support the concept. The MeSH terms used for the Medline search were selected based on those used in several of the recent notable publications on this topic. The bibliographies of the eight papers included in the meta-analysis were also reviewed and contained no additional relevant papers not identified from the Medline search. Translated abstracts of all non-English papers matching the MeSH terms were reviewed,

however none met the inclusion criteria, rather they predominantly studied acute presentations of vertebral body osteomyelitis and discitis.

Following from the literature review, two projects were conducted simultaneously. The first project sought to identify an association between the presence of P. Acnes in intervertebral disc material, and Modic changes on pre-operative magnetic resonance imaging. This aimed to answer two questions, firstly whether there is evidence of actual P. Acnes infection in discs, and secondly whether pre-operative MRI could be used as a predictor of infection. If a reliable and non-invasive diagnostic test of low-grade P. Acnes disc infection cannot be identified, then appropriate selection of patients for antibiotic therapy would be difficult. This would likely lead to overtreatment and contribute to worldwide antimicrobial resistance.

The second project sought to identify differences in long term outcomes after spinal surgery. If the first project was unable to find evidence that Modic changes were a sign of low-grade infection of the disc, there may be another, unidentified reason for a difference in post-operative results between those with and without Modic changes.

Chapter 1

Literature Review – Do Bacteria Play an Important Role in the Pathogenesis of Low Back Pain?

Thomas J. Fisher, Orso L. Osti

Centre for Orthopaedic and Trauma Research

School of Medicine

Faculty of Health Sciences

University of Adelaide

ANZ Journal of Surgery – Published Paper

ANZ J Surg. 2015 Nov;85(11):808-814. doi: 10.1111/ans.12983.

Fisher, T.J. & Osti, O.L. (2015). Do Bacteria Play an Important Role in the Pathogenesis of Low Back Pain?
ANZ Journal of Surgery, 85(11), 808-814.

NOTE:

This publication is included on pages 9 - 15 in the print copy of the thesis held in the University of Adelaide Library.

It is also available online to authorised users at:

<http://dx.doi.org/10.1111/ans.12983>

Chapter 2

Modic Changes: Do They Predict Growth of Propionibacterium Acnes in Intervertebral Disc Material?

Thomas J. Fisher, Orso L. Osti

Centre for Orthopaedic and Trauma Research

School of Medicine

Faculty of Health Sciences

University of Adelaide

European Journal of Spine – Submitted Paper

The review of literature on this topic confirmed that far from a consensus being achieved, significant disagreement existed. While a small number of papers were supportive of this hypothesis, many authors reported findings more suggestive of contamination of specimens during collection as a source of P. Acnes.

In an effort to examine the claim that Modic changes are predictive of bacterial infection of the disc, a study was undertaken to compare microbiological and radiological findings in patients undergoing open spinal surgery. The primary interest in the utility of Modic changes as a predictor of bacterial infection was to establish a marker of infection that could be used in clinical practice, such that patients could potentially avoid surgery in favour of antibiotic treatment.

Modic Changes: Do They Predict Growth of *Propionibacterium Acnes* in Intervertebral Disc Material?

Abstract

Study Design

Cross-sectional study

Objective

To identify clinically useful associations between clinical, radiological and histopathological data and the detection of bacteria in intervertebral discs.

Summary of Background Data

Recent studies have generated controversy in the treatment of chronic lower back pain in the setting of intervertebral disc herniation. Some authors believe a subacute bacterial infection with organisms such as *Propionibacterium Acnes* drives many patients' symptoms that do not respond to conservative treatments, and that the current surgical options may be unnecessary.

Aim

Our study aimed to identify whether any factors could be identified preoperatively that would predict which patients grow bacteria from intervertebral disc specimens, and therefore that would have otherwise been candidates for antimicrobial therapy.

Methods

Intervertebral disc specimens were collected from 54 patients undergoing spinal surgery for various indications. Extended bacterial culture and *Propionibacterium Acnes* PCR testing was

performed, and results compared with pre-operative pain score, MRI findings and other clinical data.

Results

Neither presence of Modic changes nor herniation of intervertebral disc were predictive of subsequent bacterial identification. The only statistically significant predictor of *Propionibacterium Acnes* identification was prior history of open spinal surgery.

Conclusions

Although evidence exists for the efficacy of antibiotic therapy in a subset of patients presenting with chronic low back pain, convincing evidence of the causal link between symptoms and a bacterial pathogen are lacking. Association between bacterial infection and Modic changes could not be reproduced.

Keywords

Humans

Low Back Pain

Modic changes

Intervertebral Disc/microbiology

Intervertebral Disc Displacement

Sciatica

Propionibacterium acnes/isolation & purification

Surgical Wound Infection/microbiology

Lumbar Vertebrae/microbiology

Bacteria/isolation and purification

Polymerase Chain Reaction

Key Points

1. Controversy exists around the theory that *Propionibacterium Acnes* may cause low grade infection of the herniated intervertebral disc, resulting in some patients not responding to conservative treatment of their pain.
2. Although a lack of convincing evidence is available that *Propionibacterium Acnes* causes a true low grade infection in the disc, treatment of patients with oral antibiotics has shown impressive results.
3. Our study could not find any association between any clinical, radiological or histopathological data and the identification of bacteria in the intervertebral disc, except a past history of open spinal surgery.
4. There is insufficient evidence that bacterial identification represents more than contamination of specimens during open surgery to support a significant change in practice.

Mini Abstract

A controversial theory has emerged that chronic low back pain is caused by low grade infection of the intervertebral disc with *Propionibacterium Acnes*. Our series of disc cultures could find no predictors of bacterial infection, except history of prior open spinal surgery.

Introduction

Chronic low back pain places a major strain on the global community both socially and economically¹. While the patient presenting with persistent low back and leg pain as well as radiological evidence of herniated nucleus pulposus (HNP) may typically be offered surgical intervention in the form of microdiscectomy, a competing treatment strategy is emerging.

Since the identification by Stirling et al² of *Propionibacterium Acnes* (P. Acnes) in samples of herniated intervertebral discs, interest in this area has grown considerably. Although bacteria were identified in herniated discs, a control group in this study found no evidence of bacteria in the discs of patients without herniation (undergoing surgery for indications such as trauma or scoliosis). Albert et al have studied this hypothesis, finding a temporal correlation between the presence of P. Acnes in herniated discs and subsequent development of type one Modic changes on follow up imaging³. The same group had remarkable success in treating patients with HNP and type one Modic changes with extended courses of oral antibiotics in a double blind randomised controlled trial⁴. Albert proposed that the presence of type one Modic changes in adjacent vertebral endplates is an indicator that the disc may harbour P. Acnes. This patient population would therefore be amenable to treatment with antibiotics rather than invasive surgery³.

While not mutually exclusive, this theory proposes that radiculopathy in the setting of intervertebral disc herniation is due to an inflammatory response from bacterial infection, rather than the previously accepted mechanism of mechanical compression and chemical irritation⁵⁻⁸.

These papers have attracted great interest and stern criticism, and several other studies have suggested bacterial growth from intervertebral disc specimens collected during open surgery represent contamination from wound and subcutaneous tissue flora rather than any true clinically relevant infection⁹⁻¹¹. Positive bacterial culture rates vary widely between authors, ranging from 6.7%¹⁰ to 48.2%¹². The most common organisms identified are *P. Acnes* followed by Coagulase Negative Staphylococci¹³.

This study aimed to identify whether the presence of Modic changes, or any other clinical data was associated with the identification of *P. Acnes* in the intervertebral disc and therefore be a useful tool in guiding treatment.

Methods

Patient selection

Ethical approval was obtained from our institutional human research ethics committee. Patients from a single spinal surgeon's practice were prospectively recruited. All patients undergoing spinal surgery where intervertebral disc material was planned to be removed were included, including from the cervical spine. Exclusion criteria were age less than 18 years, inability to give informed consent due to cognitive or language barriers and prior history of local spinal infection. Patients were not excluded on the basis of prior open or percutaneous surgical procedures.

Clinical information collected

After gaining informed consent, clinical information was collected pre-operatively. This included patient demographics, Oswestry Disability Index (ODI), Visual Analogue Score (VAS) and history of immunosuppression. Previous spinal interventions were recorded and classed as either open surgery or percutaneous procedures (such as radiologically guided epidural or foraminal injections, or radiofrequency neurotomy).

Radiological analysis

Patient MRI scans were reviewed electronically using InteleViewer (Intelrad Medical Systems Incorporated). The presence of MCs and intervertebral disc pathology were recorded. As MRIs were performed prior to patient recruitment and therefore at various radiology practices in the local area, no standardised MRI protocol was used. Wherever possible, imaging was directly reviewed by the author. All MRIs were formally reported by a consultant radiologist. In cases where an MRI report was available but no images, the radiologist's report was reviewed with respect to intervertebral disc herniation. As comment on the presence of Modic changes was inconsistent and infrequent in radiologist's reports, these patients were excluded from analysis regarding Modic changes.

Specimen Collection

Skin preparation was performed using 2% chlorhexidine in 70% isopropyl alcohol and allowed approximately 2 minutes to evaporate. All patients received routine prophylactic antibiotics prior to skin incision, typically cephazolin. Intervertebral disc material was harvested with the use of a rongeur, and transferred to a clean sterile pack for dissemination into two sterile specimen containers. Where the procedure involved multiple spinal levels, disc material was collected from the first operative level to reduce risk of contamination

during prolonged procedures. One specimen was stored fresh and the other stored in formalin.

Specimen Processing

Disc specimens were processed by a single laboratory. Fresh specimens were separated into two, one half of which underwent Gram stain, microscopy, culture and sensitivity testing. Aerobic culture was performed under 5% CO₂, using chocolate agar, horse blood agar, cysteine lactose electrolyte deficient (CLED) agar and cooked meat broth media. Anaerobic culture was performed using horse blood agar and horse blood agar plus neomycin media. All specimens were cultured for 14 days, as is suggested for the optimisation of *P. Acnes* identification in the setting of prosthetic joint infection¹⁴.

The other half of the fresh specimen was frozen, before being thawed at a later date for batch PCR analysis to detect the presence of *P. Acnes* DNA. PCR analysis was performed using a proprietary QIAGEN microbial DNA qPCR assay (QIAGEN Pty Ltd. Melbourne, Australia) specific for the detection of *P. Acnes* DNA.

Specimens stored in formalin were stained using haematoxylin & eosin, and reviewed by a consultant pathologist with respect to presence of inflammatory cells and neovascularisation (figure 1).

Statistical Analysis

Statistical analysis was performed using SPSS Statistics 22 (IBM Corporation, Somers, New York). Fisher's exact test was used to determine significance of associations between clinical factors and *P. Acnes* identification. A p value <0.05 was considered statistically significant.

Results

Clinical Information

Informed consent was obtained from 54 patients to participate in the study (table 1). 33 males (61.1%) were recruited. Mean ODI was 44.2% (SD 16.9%) (table 2) and mean VAS was 5.7 (SD 2.2). Mean age at time of surgery was 55.9 years (SD 13.9), and mean self-reported time with pain prior to surgery was 5.9 years (SD 8.5). 34 patients (62.9%) underwent single level surgery.

Radiology

51 (94.4%) patients underwent a pre-operative MRI. 3 patients did not either due to claustrophobia or for safety reasons. Images from 1 MRI were unable to be viewed, however a consultant radiologist report was available.

Review of imaging found 38 of 51 (74.5%) patients had herniation of an intervertebral disc at their operative level. 23 of 50 (46%) patients were identified as having Modic changes at one or more operative level, with a further 4 (8%) of patients found to have Modic changes not at the operative site.

Bacterial Identification

10 of 53 (18.9%) disc specimens on which microbiological culture was performed grew bacteria (table 3). 9 of 10 (90%) positive cultures were for *P. Acnes*, the other positive culture being for *Acinetobacter*.

14 of 54 (25.9%) disc specimens on which *P. Acnes* PCR analysis was performed identified *P. Acnes* DNA.

2 discs that grew *P. Acnes* on culture were found to be PCR negative, and 7 discs that showed no bacterial growth were found to be PCR positive.

P. Acnes was identified in a total of 16 (29.6%) discs.

Histopathological Analysis

Histopathological review of 52 discs was performed. No significant acute inflammatory changes were observed in any discs, however 5 of 52 (9.6%) showed evidence of neovascularisation (table 4).

Associations

P. Acnes was found in 11 of 38 (28.9%) herniated discs, as compared with 5 of 13 (38.5%) without disc herniation. 6 of 23 (26.1%) discs with adjacent Modic changes were found positive for *P. Acnes*, compared with 9 of 27 (33.3%) discs where no Modic changes were present. None of the 6 patients with type 1 Modic changes at the operative site had *P. Acnes* identified, although this difference was not significant. There was no statistically significant correlation between the presence of a herniated disc or Modic changes at adjacent levels and the subsequent detection of *P. Acnes*.

History of diabetes mellitus or any other form of immunosuppression was not associated with higher rates of *P. Acnes* detection, however a significant difference was seen in patients who had undergone previous open spinal surgery, relative to either percutaneous interventions or no intervention (42.9% vs 25.0% $p=0.0468$).

Male participants showed a non-significant trend towards higher rates of *P. Acnes*, however this is likely confounded by the considerably higher rate of prior open spinal surgery compared with female participants.

Neovascularisation was no more likely to be found in discs that were radiologically herniated than those that were not, and this was not associated with a higher rate of *P. Acnes* identification.

Mean ODI scores were similar between groups based on gender, disc integrity, presence of MCs and *P. Acnes* result without any trend towards more severe symptoms.

Discussion

Low grade anaerobic bacterial infection of the intervertebral disc has been hypothesised as a cause for chronic low back pain in the presence of disc herniation³. Extended courses of oral antibiotics have been proposed as a treatment alternative, sparing patients the risks and morbidity of open spinal surgery such as microdiscectomy. Such a treatment regime is not without its own drawbacks however, with risks including gastrointestinal upset, as well as increasing prevalence of resistant bacteria in the community. Albert et al⁴ propose this treatment strategy for patients with persistent low back pain and type 1 Modic changes who have failed other conservative options.

The findings of this study do not support the disc infection hypothesis. *P. Acnes* was identified in 29.6% of patients, marginally higher than the average across other similar studies¹³ despite routine administration of prophylactic antibiotics prior to specimen collection. Although antibiotic administration does appear to decrease yield of bacteria in other studies¹³, cephalosporins seem to penetrate the disc in only low concentrations¹⁵.

Contamination during specimen collection has been proposed as an alternative explanation for the frequent detection of bacteria from intervertebral discs. McLorinan et al¹¹ and Carricajo et al⁹ identified *P. Acnes* and CoNS in samples of skin, deeper tissue, muscle

biopsies, wound washings and even air samples taken intra-operatively. *P. Acnes* was also cultured from control media exposed to laminar air flow in cabinets used for plating of specimens⁹, suggesting contamination can occur well after initial collection has taken place. They theorised that colonisation of hair follicles by *P. Acnes* allows it to escape the effects of surgical skin preparation, and once the skin has been incised, bleeding transports it deeper into the wound.

No clinical indicators could be identified to predict whether *P. Acnes* would subsequently be detected in disc specimens. It is postulated that bacteria gain entry to the disc following herniation and neovascularisation¹⁶, and that Modic changes reflect an inflammatory response to infection. In our study however, neither the presence of disc herniation, Modic changes or neovascularisation were predictive of *P. Acnes* detection.

Despite a lack of supportive evidence from other authors for *P. Acnes* infection as a cause of chronic LBP, Albert et al⁴ found antibiotic treatment for the condition to be remarkably effective compared with placebo. It is possible however that amoxicillin and clavulanic acid may have an anti-inflammatory effect, resulting in relief from pain and improved functional outcomes independent of any antimicrobial effect.

Conclusion

This study is not able to refute the hypothesis that low grade *P. Acnes* infection in intervertebral discs is a cause for chronic pain. Only one of the factors investigated however, had any statistically significant association with the identification of *P. Acnes*. Of note, data normally collected during assessment of the patient with chronic LBP such as integrity of the

disc and presence of Modic changes in adjacent endplates on MRI were not predictors of P. Acnes.

Contamination of surgical specimens presents a challenge to both research and clinical work, due to the uncertainty of the significance of findings. P. Acnes is recognised as a cause of low grade prosthetic infections¹⁷ and a rare cause of infection following spinal surgery¹⁸. It has also been identified as a contaminant during open surgical procedures, in particular of the upper limb^{19,20}.

Compelling doubt exists over the utility of the proposed antibiotic treatment regime. The results of this study suggest there are no clinical indicators yet established that could be used to determine whether a patient presenting with chronic LBP should be treated with antibiotics. While such a treatment could be considered in individual circumstances as a last resort where surgery is not a suitable option, it would be premature to recommend it as a widespread alternative to surgery. Such a patient should be counselled about the uncertain benefit, and risk of side effects.

Further research is needed to validate or refute this hypothesis, with a specific focus on the distinction between true infection and contamination, whether by direct means or indirect surrogate indicators.

References

1. Buchbinder R, Blyth FM, March LM, et al. Placing the global burden of low back pain in context. *Best practice & research. Clinical rheumatology* 2013;27:575-89.
2. Stirling A, Worthington T, Rafiq M, et al. Association between sciatica and Propionibacterium acnes. *Lancet* 2001;357:2024-5.

3. Albert HB, Lambert P, Rollason J, et al. Does nuclear tissue infected with bacteria following disc herniations lead to Modic changes in the adjacent vertebrae? *Eur Spine J* 2013;22:690-6.
4. Albert HB, Sorensen JS, Christensen BS, et al. Antibiotic treatment in patients with chronic low back pain and vertebral bone edema (Modic type 1 changes): a double-blind randomized clinical controlled trial of efficacy. *Eur Spine J* 2013;22:697-707.
5. Olmarker K, Rydevik B, Nordborg C. Autologous nucleus pulposus induces neurophysiologic and histologic changes in porcine cauda equina nerve roots. *Spine (Phila Pa 1976)* 1993;18:1425-32.
6. Yabuki S, Igarashi T, Kikuchi S. Application of nucleus pulposus to the nerve root simultaneously reduces blood flow in dorsal root ganglion and corresponding hindpaw in the rat. *Spine (Phila Pa 1976)* 2000;25:1471-6.
7. Yabuki S, Kikuchi S, Olmarker K, et al. Acute effects of nucleus pulposus on blood flow and endoneurial fluid pressure in rat dorsal root ganglia. *Spine (Phila Pa 1976)* 1998;23:2517-23.
8. Lidslot L, Olmarker K, Kayama S, et al. Nucleus pulposus inhibits the axonal outgrowth of cultured dorsal root ganglion cells. *Eur Spine J* 2000;9:8-13.
9. Carricajo A, Nuti C, Aubert E, et al. Propionibacterium acnes contamination in lumbar disc surgery. *J Hosp Infect* 2007;66:275-7.
10. Ben-Galim P, Rand N, Giladi M, et al. Association between sciatica and microbial infection: true infection or culture contamination? *Spine (Phila Pa 1976)* 2006;31:2507-9.
11. McLorinan GC, Glenn JV, McMullan MG, et al. Propionibacterium acnes wound contamination at the time of spinal surgery. *2005* 2005:67-73.

12. Arndt J, Charles YP, Koebel C, et al. Bacteriology of degenerated lumbar intervertebral disks. *J Spinal Disord Tech* 2012;25:E211-6.
13. Fisher TJ, Osti OL. Do bacteria play an important role in the pathogenesis of low back pain? *ANZ journal of surgery* 2015.
14. Butler-Wu SM, Burns EM, Pottinger PS, et al. Optimization of periprosthetic culture for diagnosis of *Propionibacterium acnes* prosthetic joint infection. *Journal of clinical microbiology* 2011;49:2490-5.
15. Fraser RD, Osti OL, Vernon-Roberts B. Iatrogenic discitis: the role of intravenous antibiotics in prevention and treatment. An experimental study. *Spine (Phila Pa 1976)* 1989;14:1025-32.
16. Albert HB, Kjaer P, Jensen TS, et al. Modic changes, possible causes and relation to low back pain. *Med Hypotheses* 2008;70:361-8.
17. Lutz MF, Berthelot P, Fresard A, et al. Arthroplastic and osteosynthetic infections due to *Propionibacterium acnes*: a retrospective study of 52 cases, 1995-2002. *European journal of clinical microbiology & infectious diseases : official publication of the European Society of Clinical Microbiology* 2005;24:739-44.
18. Haidar R, Najjar M, Der Boghossian A, et al. *Propionibacterium acnes* causing delayed postoperative spine infection: review. *Scand J Infect Dis* 2010;42:405-11.
19. Maccioni CB, Woodbridge AB, Balestro JC, et al. Low rate of *Propionibacterium acnes* in arthritic shoulders undergoing primary total shoulder replacement surgery using a strict specimen collection technique. *Journal of shoulder and elbow surgery / American Shoulder and Elbow Surgeons ... [et al.]* 2015;24:1206-11.

20. Hudek R, Sommer F, Kerwat M, et al. Propionibacterium acnes in shoulder surgery: true infection, contamination, or commensal of the deep tissue? *Journal of shoulder and elbow surgery / American Shoulder and Elbow Surgeons ... [et al.]* 2014;23:1763-71.

Tables

Table 1

Total patients	54
Mean age (+/- SD)	55.9 (+/-13.9)
Mean ODI (+/- SD)	44.2% (+/-16.9)
Mean VAS (+/- SD)	5.7 (+/-2.2)
Mean Time with Pain (years) (+/- SD)	5.9 (+/-8.5)
History of Prior Open Surgery (male)	12/33 (36.4%)
History of Prior Open Surgery (female)	2/21 (9.5%)

Patient demographics

Table 2

	Mean ODI (95% CI)
Patients	
Male	43.8% (37.3-50.3%)
Female	44.8% (35.9-53.7%)
Disc Herniated	42.1% (36.1-48.0%)
Not Herniated	48.4% (38.4-58.4%)
MCs Present	46.9% (38.4-55.3%)
No MCs Present	41.1% (34.8-47.5%)
P. Acnes Positive	47.9% (38.5-57.2%)
P. Acnes Negative	41.7% (35.6-47.8%)

Mean ODI scores separated on the basis of clinical data

Table 3

	n=	P. Acnes Positive	P. Acnes Negative	p=
Patients	54	16 (29.6%)	38 (70.4%)	
Male	33	13 (39.4%)	20 (60.6%)	0.068
Female	21	3 (14.3%)	18 (85.7%)	
Disc Herniated	38	11 (28.9%)	27 (71.1%)	0.730
Not Herniated	13	5 (38.5%)	8 (61.5%)	
No MCs Present	27	9 (33.3%)	18 (66.7%)	0.758
MCs Present	23	6 (26.1%)	17 (73.9%)	
Type 1 MCs Present	6	0	6 (100%)	0.160
Lumbar Spine	49	13 (26.5%)	36 (73.5%)	0.148
Cervical Spine	5	3 (60%)	2 (40%)	
No Neovascularisation	47	13 (27.7%)	34 (72.3%)	0.619
Neovascularisation	5	2 (40%)	3 (60%)	
Nil Previous Intervention	19	5 (26.3%)	14 (73.7%)	0.0468
Percutaneous Intervention	21	5 (23.8%)	16 (76.2%)	
Open Surgery	14	6 (42.9%)	8 (57.1%)	
No immunosuppression	44	13 (29.5%)	31 (70.5%)	1.0
Immunosuppressants	2	0	2 (100%)	
Diabetes Mellitus	8	3 (37.5%)	5 (62.5%)	

Breakdown of P. Acnes identification on the basis of pre-operative clinical information, radiological and histological findings.

P value for open surgery calculated against nil and percutaneous intervention combined. P value for immunosuppression calculated by combining immunosuppression and diabetes mellitus. P value for Type 1 MCs calculated against no MCs present and other types of MCs combined.

Table 4

	n=	Neovascularisation	No Neovascularisation	p=
Disc Herniated	36	4 (11.1%)	32 (88.9%)	1.0
Not Herniated	13	1 (7.7%)	12 (92.3%)	

Correlation between radiological disc herniation and microscopic evidence of neovascularisation

Figures

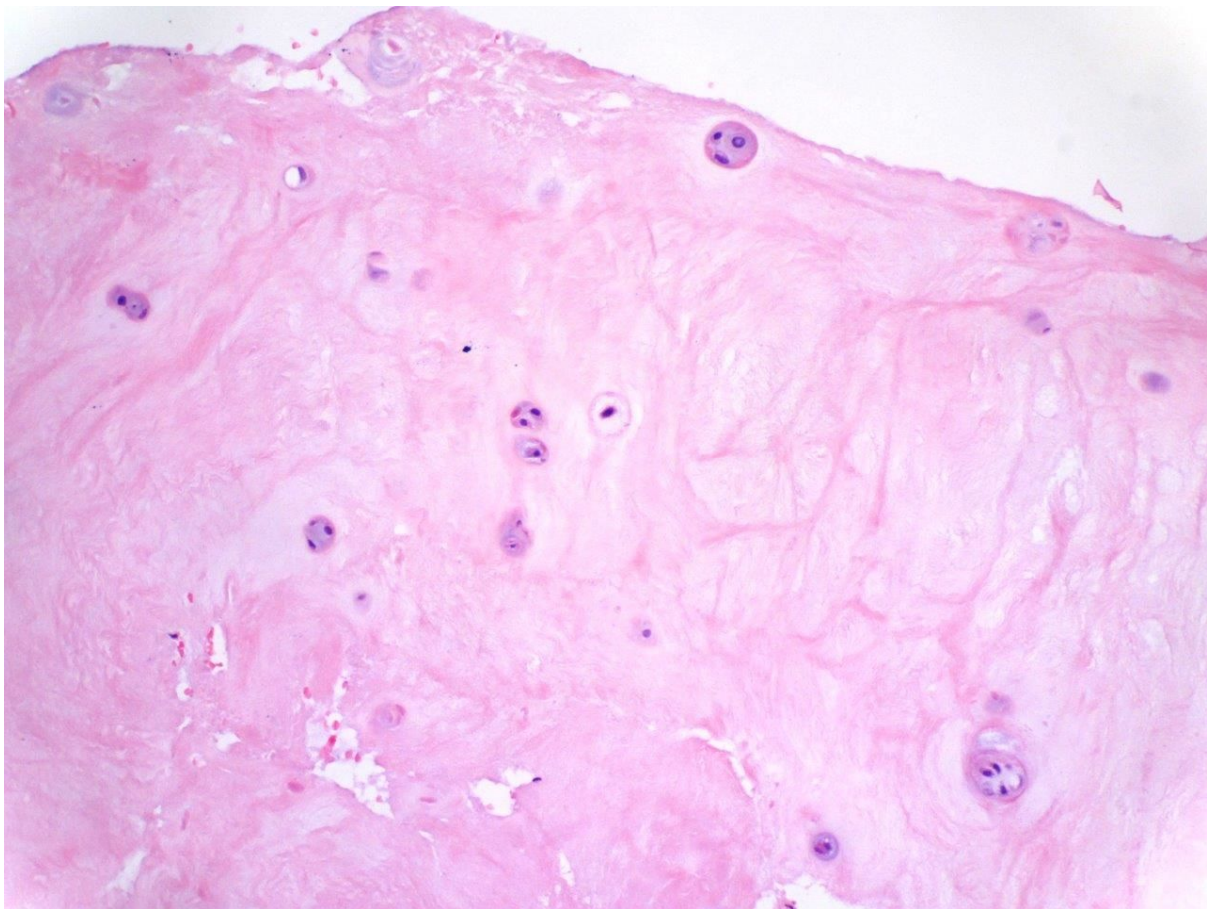


Figure 1(a) Fibrocartilage of normal intervertebral disc.

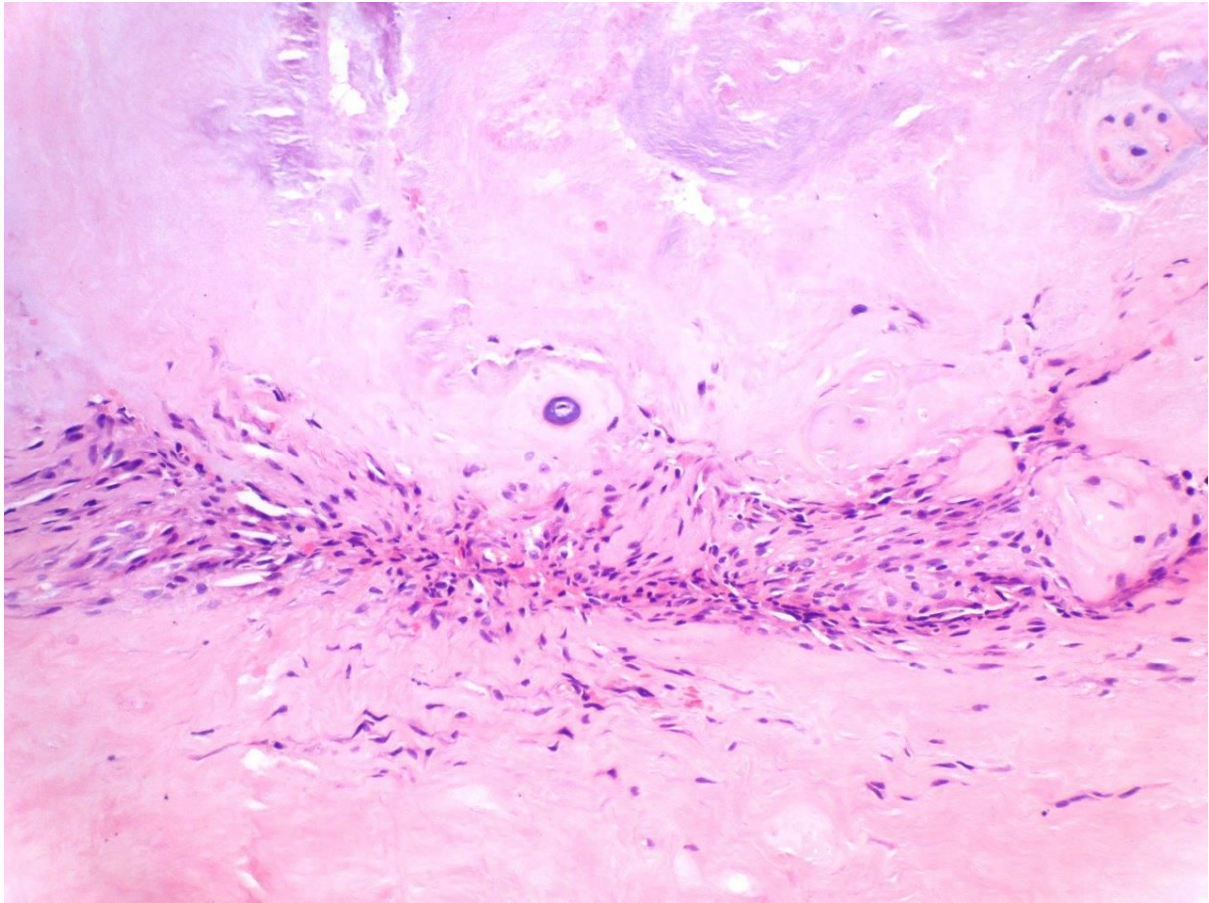


Figure 1(b) Granulation tissue in intervertebral disc, representing response to injury.

Chapter 3

Modic Changes and Surgical Outcomes

Thomas J. Fisher, Orso L. Osti

Centre for Orthopaedic and Trauma Research

School of Medicine

Faculty of Health Sciences

University of Adelaide

European Journal of Spine – Submitted Paper

Having identified P. Acnes in disc specimens but without any association with pre-operative imaging, the next step was to establish whether patients undergoing surgery had different outcomes based on Modic changes, a surrogate marker for infection. In the absence of sufficient debridement of infected tissue and appropriate antimicrobial therapy, it was thought that, if a true infection was present, such a patient would have a poorer outcome following surgery.

A follow-up study was undertaken in patients who had undergone open procedures approximately two years earlier. The Oswestry Disability Index (a measure of severity of back pain) had been collected pre-operatively as part of routine patient assessment and this test was repeated in addition to review of pre-operative imaging.

Response rate in this study was poor, and the relatively small numbers resulted in an underpowered study. No significant difference was observed between those patients with Modic changes at corresponding vertebral levels and those without.

Modic Changes and Surgical Outcomes

Abstract

Introduction: Low back pain remains a difficult entity to treat, both surgically and non-surgically. Modic changes have been the target of interest for research over several decades however their presence remains a difficult problem to define.

Aim: This study aimed to establish whether the presence of Modic changes at operative levels in patients undergoing spinal surgery for segmental stabilisation, discectomy, or both was predictive of poorer long term outcomes.

Methods: A retrospective review of patients from a single surgeon's practice was conducted. Oswestry Disability Index (ODI) and Visual Analogue Score for pain were routinely collected pre-operatively and these were repeated as follow-up via mail.

Results: 19 of 98 (19.4%) patients contacted responded and returned their pain score questionnaires, minimum follow-up was 21 months. There was a non-significant small trend towards weaker improvements in ODI in patients with Modic changes at operative levels. Compensable patients had a significantly poorer outcome than non-compensable patients.

Conclusion: The presence of Modic changes at the operative level in patients undergoing discectomy and segmental stabilisation may have a slightly poorer post-operative prognosis but this difference was not substantial or significant.

Introduction

Modic changes (MCs) are the target of considerable interest in the spinal surgery community. First described in 1988^{1,2}, they are strongly associated with symptomatic low back pain (LBP)³ and appear on spinal magnetic resonance imaging (MRI) in regions together with

other disc pathology⁴. A recent study of the microarchitecture of the vertebral endplate suggests that the three types of MCs reflect a sequential process from active inflammation and remodelling to sclerosis⁵.

The coexistence of degenerative disc disease (DDD) and MCs has been shown to cause a more severe clinical picture of LBP than in those with DDD alone on MRI, suggesting that MCs represent a critical element of the pathological process⁶.

A hypothesis has been proposed that anaerobic bacteria cause persistent LBP in the setting of herniated nucleus pulposus (HNP), resulting in development of MCs⁷. Although treatment of these patients with oral antibiotics has found superior outcomes in a randomised blinded placebo controlled study⁸, significant doubts remain about the likelihood of true infection in the disc⁹⁻¹².

Extrapolating this theory, it may be expected that open spinal surgery to either resect a portion of herniated intervertebral disc, fuse spinal segments or both would result in inferior outcomes in patients with MCs. Without prolonged antibiotic treatment this infection would not be cleared and therefore pain would persist.

Our study aimed to identify whether the presence of MCs was predictive of poorer outcomes relative to those patients without MCs at the level of their surgery.

Methods

Data Collection

A retrospective case note review was conducted from a single spinal surgeon's private practice. Operating lists were used to select patients undergoing lumbar discectomy for

symptomatic intervertebral disc herniation, lumbar spine segmental stabilisation or a combination of both.

Inclusion criteria were age greater than 18 years, minimum follow-up at least 18 months and completion of pre-operative Oswestry Disability Index (ODI) and Visual Analogue Score (VAS) questionnaires.

Exclusion criteria were age less than 18 years, inability to complete questionnaire due to cognitive or language barrier, inadequate clinical or radiological records and repeat spinal surgery within the three months preceding completion of follow-up questionnaire. Patients who had subsequently undergone removal of spinal implants were not excluded, unless this had occurred in the three months prior to contact. This was to prevent their resolving post-operative pain from confounding the results.

Retrospective data collected included age, ODI, VAS, self-reported duration of pain prior to surgery, and previous spinal interventions. Pre-operative MRIs were reviewed using IntelViewer (Intelrad Medical Systems Incorporated) and assessed for presence of intervertebral disc herniation and MCs.

Patients were allocated to one of two cohorts based on the presence or absence of Modic changes at the vertebral endplates of any operative level.

Follow up was performed by mail, asking patients to repeat ODI and VAS questionnaires.

Sample Size and Power Analysis

Published samples of chronic back pain groups have found standard deviations for ODI between 10 and 21 points¹³. The minimum clinically important difference for ODI has been estimated between four¹⁴ and 15¹³ points. Large variation in these figures prevented the precise calculation of sample size. To achieve a power of 0.8, sample size was therefore estimated to be between 8 and 394 for a one-tailed hypothesis. As this study aimed to identify

large differences in outcomes, a mean difference in ODI of 15 points was considered significant, as suggested by the US Food and Drug Administration¹³. Assuming a population ODI standard deviation of 20 points, sample size was calculated as 30 patients.

Statistical Analysis

Statistical analysis was completed using SPSS Statistics 22 (IBM Corporation, Somers, New York). Student's t-test was used to compare mean values between the two cohorts and a p value < 0.05 used to determine statistical significance. The paired sample t-test was used to determine the significance of change in ODI & VAS prior to and following surgical intervention.

Results

Demographics

147 patients were identified from operating theatre lists, of whom 98 had complete clinical records suitable for review. The most common reasons for exclusion were incomplete ODI or completion of a different pain scoring questionnaire. Of 98 patients contacted, 19 (19.4%) returned follow up questionnaires and consented to participation. Mean time to follow up was 28 months (range 21-34, table 1). MCs were present at the operative site in 10 patients (52.6%). Mean self-reported time experiencing pain prior to surgery was longer in the MC cohort, however there was very high variance in both groups and as such no statistically significant difference was identified. Across both cohorts, mean change in ODI between pre-operative and post-operative assessment was -18.1% (p = 0.004) and mean change in VAS was -2.3 (p = 0.004, table 2). Overall mean pre-operative ODI was 47.2% (SD 18.0)

Modic Changes

Mean pre-operative ODI and VAS were similar between the MC and non-MC cohorts (table 3). Mean change in ODI at follow up showed greater improvement in the non-MC cohort, but

this difference was not statistically significant (table 1). This was also less than the pre-defined minimum clinically important difference of 15 points. There was no statistically significant difference in change in VAS between the two groups.

Compensable Status

Four of 19 (21.5%) patients were of compensable status. ODI scoring showed significantly greater improvement in the non-compensable group compared with the compensable patient group (table 2). Improvement in VAS was greater in the non-compensable group, but this was not statistically significant (-2.8 vs -0.5, $p=0.166$).

Prior Open Surgery

Five of 19 (26.3%) patients had undergone prior open lumbar spine surgery. Pre-operative and post-operative scoring in both groups was similar with no significant difference identified.

Discussion

Low back pain is a difficult entity despite advances in imaging modalities and surgical techniques. Modic changes remain a poorly understood feature of spinal imaging. Although evidence exists suggesting that presence of Modic changes is predictive of more severe spinal symptoms⁶, a definite pathological process of causation has yet to be identified.

Propionibacterium acnes has been postulated as a trigger for the development of Modic changes in association with intervertebral disc herniation⁷, however confirmatory evidence of this is lacking.

This study aimed to establish whether the presence of Modic changes could act as a predictor of an inferior outcome after open spinal surgery. No statistically or clinically significant difference was identified between those with pre-operative MCs and those without. Outcomes

between patients who had undergone prior open lumbar spinal surgery and those had not were very similar, suggesting that revision surgery can still be expected to achieve good outcomes.

Our study was underpowered due to a poor response rate (19.4%) to our mail-out questionnaire, making a type 2 error likely in the absence of a very large difference between the two cohorts. A post-hoc power analysis based on the pre-operative standard deviation of ODI scores (18.0) estimated that a sample size of approximately 25 patients was necessary for a power of 0.8. An inherent weakness of mail-out questionnaires in research is participation bias. It cannot be assumed that the respondents are an accurate representation of the total cohort of patients contacted, as their individual outcomes may play a role in their decision to participate and therefore act as a confounding factor. The retrospective nature of the study also weakened the overall findings, although pre-operative pain scores were collected prospectively.

A relatively large proportion of the patient population from which this study recruited are compensable (37.3%), however only 21.1% of respondents were compensable. The mean difference in ODI surprisingly reflected a small deterioration in functional status in the compensable group, compared with considerable improvements in the non-compensable group. This finding is compatible with previous studies which have found consistently poorer outcomes in compensable patients undergoing spinal surgery¹⁵. The significantly lower response rate from compensable patients may relate to issues of secondary gain and concern regarding implications of participation related to ongoing compensation claims.

This study aimed to identify whether large differences were identifiable in patients undergoing a combination of lumbar fusion and discectomy who had MCs at operative levels

and those that did not. While a trend towards improved outcomes was identified in the non-MC cohort, the difference was relatively small and not statistically significant. A larger study would be able to more confidently confirm or refute this trend. Mail-out questionnaires typically result in relatively low response rates, and therefore a face to face encounter for long term follow up may be one method in which to improve participation.

References

1. Modic MT, Masaryk TJ, Ross JS, et al. Imaging of degenerative disk disease. *Radiology* 1988;168:177-86.
2. Modic MT, Steinberg PM, Ross JS, et al. Degenerative disk disease: assessment of changes in vertebral body marrow with MR imaging. *Radiology* 1988;166:193-9.
3. Jensen TS, Karppinen J, Sorensen JS, et al. Vertebral endplate signal changes (Modic change): a systematic literature review of prevalence and association with non-specific low back pain. *Eur Spine J* 2008;17:1407-22.
4. Albert HB, Briggs AM, Kent P, et al. The prevalence of MRI-defined spinal pathoanatomies and their association with modic changes in individuals seeking care for low back pain. *Eur Spine J* 2011;20:1355-62.
5. Perilli E, Parkinson IH, Truong LH, et al. Modic (endplate) changes in the lumbar spine: bone micro-architecture and remodelling. *Eur Spine J* 2014.
6. Kjaer P, Korsholm L, Bendix T, et al. Modic changes and their associations with clinical findings. *Eur Spine J* 2006;15:1312-9.
7. Albert HB, Lambert P, Rollason J, et al. Does nuclear tissue infected with bacteria following disc herniations lead to Modic changes in the adjacent vertebrae? *Eur Spine J* 2013;22:690-6.

8. Albert HB, Sorensen JS, Christensen BS, et al. Antibiotic treatment in patients with chronic low back pain and vertebral bone edema (Modic type 1 changes): a double-blind randomized clinical controlled trial of efficacy. *Eur Spine J* 2013;22:697-707.
9. Fisher TJ, Osti OL. Do bacteria play an important role in the pathogenesis of low back pain? *ANZ journal of surgery* 2015.
10. Carricajo A, Nuti C, Aubert E, et al. Propionibacterium acnes contamination in lumbar disc surgery. *J Hosp Infect* 2007;66:275-7.
11. Ben-Galim P, Rand N, Giladi M, et al. Association between sciatica and microbial infection: true infection or culture contamination? *Spine (Phila Pa 1976)* 2006;31:2507-9.
12. Fritzell P, Bergstrom T, Welinder-Olsson C. Detection of bacterial DNA in painful degenerated spinal discs in patients without signs of clinical infection. *Eur Spine J* 2004;13:702-6.
13. Roland M, Fairbank J. The Roland-Morris Disability Questionnaire and the Oswestry Disability Questionnaire. *Spine (Phila Pa 1976)* 2000;25:3115-24.
14. Meade T. Comparison of chiropractic and hospital outpatient management of low back pain: a feasibility study. Report of a working group. *Journal of epidemiology and community health* 1986;40:12-7.
15. Prasarn ML, Horodyski MB, Behrend C, et al. Negative effects of smoking, workers' compensation, and litigation on pain/disability scores for spine patients. *Surgical neurology international* 2012;3:S366-9.

Tables

Table 1

	MC Cohort n=10	Non-MC Cohort n=9	P value
Age (years)	51.4 (9.7)	58.3 (11.6)	0.179
Time with Pain (months)	42.9 (42.1)	27 (27.9)	0.640
Follow Up (months)	35.4 (5.2)	26 (4.7)	0.348

Mean (+/- SD)

Table 2

	Mean Difference (all patients)	P value
ODI	-18.1% (95%CI= -6.8 – -29.5)	0.004*
VAS	-2.3 (95%CI = -0.8 – -3.7)	0.004*

Table 3

	MC Cohort n=10	Non-MC Cohort n=9	P value
Pre-Op ODI	47.3% (10.0)	47.1% (24.8)	0.984
Post-Op ODI	34.2% (22.5)	23.3% (20.1)	0.284
ODI Change	-13.1% (24.3)	-23.8% (22.8)	0.338
Pre-Op VAS	6.0 (1.4)	6.0 (2.8)	1.0
Post-Op VAS	4.4 (3.0)	3.1 (2.7)	0.341
VAS Change	-1.7 (3.0)	-2.9 (2.8)	0.382

Mean (+/- SD)

Table 4

	Compensable n=4	Non-Compensable n=15	P value
Pre-Op ODI	52.0% (3.7)	45.9% (20.1)	0.563
Post-Op ODI	55.0% (8.2)	22.1% (18.4)	0.003*
ODI Change	+3.0% (5.3)	-23.8% (23.4)	0.04*
Pre-Op VAS	6.3 (2.2)	5.9 (2.2)	0.8
Post-Op VAS	5.8 (1.9)	3.3 (2.9)	0.126
VAS Change	-0.5 (1.3)	-2.8 (3.0)	0.166

Mean (+/- SD)

Table 5

	Prior Surgery n=5	No Prior Surgery n=14	P value
Pre-Op ODI	47.4% (15.1)	47.1% (19.4)	0.951
Post-Op ODI	30.8% (21.0)	28.4% (22.5)	0.839
ODI Change	-16.8% (17.9)	-18.6% (25.9)	0.890
Pre-Op VAS	5.8 (1.6)	6.1 (2.4)	0.814
Post-Op VAS	4.0 (2.9)	3.7 (2.9)	0.854
VAS Change	-1.8 (2.6)	-2.5 (3.0)	0.674

Figures

Figure 1

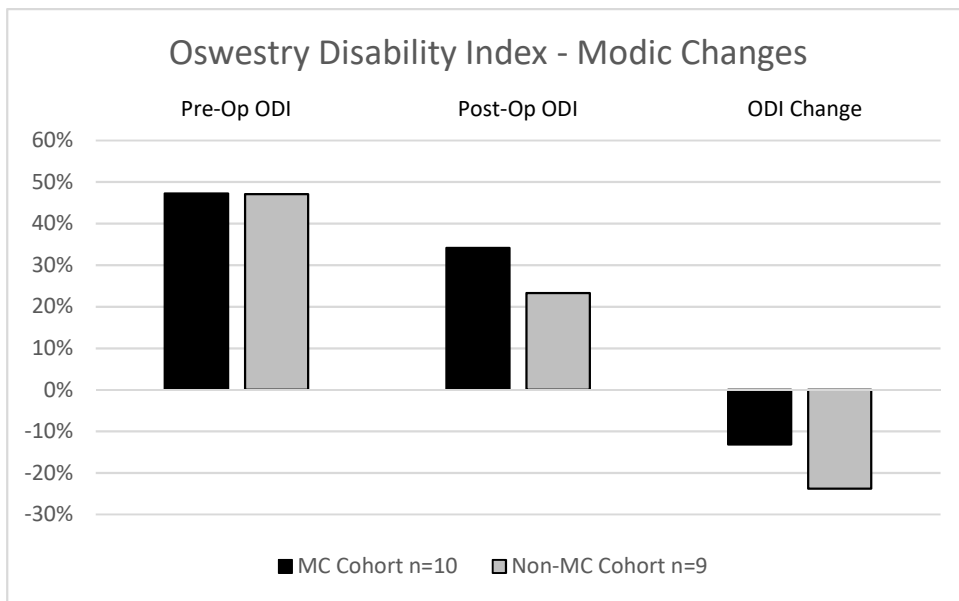
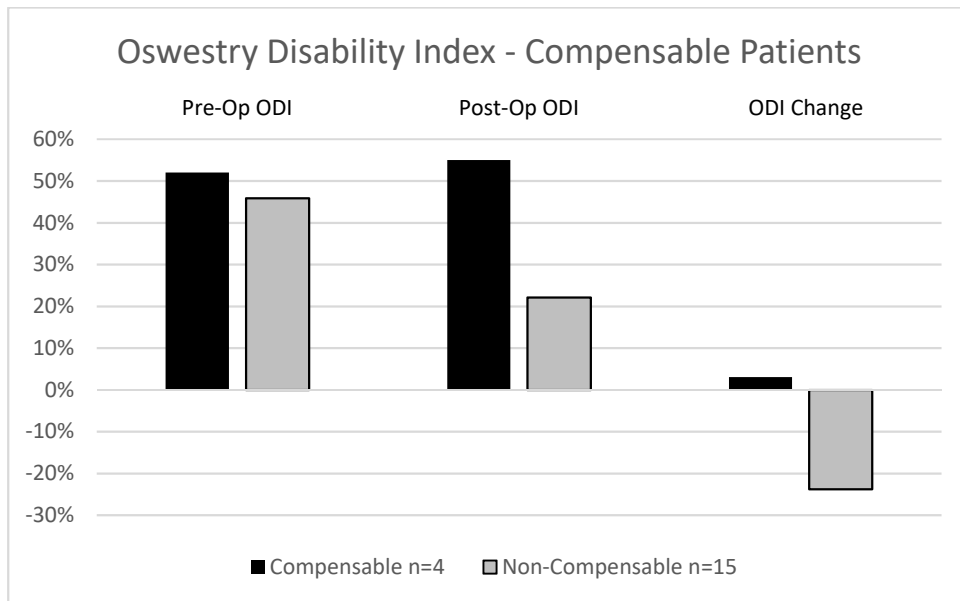


Figure 2



Discussion

The treatment of spinal pathology presents a challenge to the clinician in the best of circumstances. Recovery is often incomplete and both comorbid depression and the frequency of ongoing compensation claims further complicate effective treatment. A novel hypothesis has been proposed that low grade anaerobic bacterial infection is a cause for the chronic low back and leg pain experienced by a relatively small number of patients in whom symptoms do not resolve⁶.

The findings from this research project do not support this hypothesis or the proposed change in approach to treatment. A comprehensive review of the literature was unable to identify sufficient evidence that bacteria cultured from disc specimens did not reflect contamination during the collection process. Evidence was also lacking regarding any reliable method with which to identify which patients may be suffering such an infection that could be treated with antibiotic therapy.

The analysis of disc specimens performed in this study showed no such association between Modic changes on pre-operative MRI and subsequent identification of bacteria. It is interesting that *P. Acnes* appears to be the dominant microbe identified in cultures across multiple authors, however many also reported growth of Coagulase negative Staphylococci (CoNS)⁷⁻⁹, another known commensal organism of the skin. Our study found no evidence of CoNS, which may potentially reflect a superior sterile technique in avoiding contamination of skin. In the absence of convincing evidence that *P. Acnes* identified in specimens reflects true infection however, this assertion is not strong.

In seeking alternative reasons why patients with Modic changes in vertebral endplates may be treatable with antibiotics, we attempted to show that such patients had poorer long term

outcomes after surgical intervention. This study was relatively underpowered due to a poor response rate, and its findings weakened by its retrospective design. Initial pain scores however were collected prospectively and time to follow up was sufficient to consider that symptoms had stabilised. It found no difference between the groups, although numbers were inadequate for more detailed subgroup analysis.

While unable to strongly reject the hypothesis of disc infections, this thesis adds further weight to pre-existing doubts. The very existence of such a clinical condition is questionable, and in the absence of a reliable marker to use as a diagnostic tool, it would be difficult to justify an alternative method of treatment. The results of this thesis would caution against any change in clinical practice at this point in time.

References

- [1] Buchbinder R, Blyth FM, March LM, Brooks P, Woolf AD, Hoy DG. Placing the global burden of low back pain in context. *Best practice & research Clinical rheumatology*. 2013; 27:575-89.
- [2] Olmarker K, Rydevik B, Nordborg C. Autologous nucleus pulposus induces neurophysiologic and histologic changes in porcine cauda equina nerve roots. *Spine (Phila Pa 1976)*. 1993; 18:1425-32.
- [3] Yabuki S, Igarashi T, Kikuchi S. Application of nucleus pulposus to the nerve root simultaneously reduces blood flow in dorsal root ganglion and corresponding hindpaw in the rat. *Spine (Phila Pa 1976)*. 2000; 25:1471-6.
- [4] Yabuki S, Kikuchi S, Olmarker K, Myers RR. Acute effects of nucleus pulposus on blood flow and endoneurial fluid pressure in rat dorsal root ganglia. *Spine (Phila Pa 1976)*. 1998; 23:2517-23.
- [5] Lidslot L, Olmarker K, Kayama S, Larsson K, Rydevik B. Nucleus pulposus inhibits the axonal outgrowth of cultured dorsal root ganglion cells. *Eur Spine J*. 2000; 9:8-13.
- [6] Albert HB, Kjaer P, Jensen TS, Sorensen JS, Bendix T, Manniche C. Modic changes, possible causes and relation to low back pain. *Med Hypotheses*. 2008; 70:361-8.
- [7] Albert HB, Lambert P, Rollason J, et al. Does nuclear tissue infected with bacteria following disc herniations lead to Modic changes in the adjacent vertebrae? *Eur Spine J*. 2013; 22:690-6.
- [8] Arndt J, Charles YP, Koebel C, Bogorin I, Steib JP. Bacteriology of degenerated lumbar intervertebral disks. *J Spinal Disord Tech*. 2012; 25:E211-6.

[9] Rollason J, McDowell A, Albert HB, et al. Genotypic and antimicrobial characterisation of *Propionibacterium acnes* isolates from surgically excised lumbar disc herniations. *BioMed research international*. 2013; 2013:530382.

Acknowledgements

I would like to thank all of those who have contributed to and supported the completion of this project.

Specific thanks go to;

Orso Osti for his vision, direction and critical eye in assisting me to find and explore an engaging topic.

David Findlay and Gerald Atkinson at The University of Adelaide for supporting my project and encouraging me to continue working.

My wife Maree de Jong for the painstaking task of proofreading my work as an outside observer.

Statement of Authorship

Title of Paper	Do bacteria play an important role in the pathogenesis of low back pain?
Publication Status	<input checked="" type="checkbox"/> Published <input type="checkbox"/> Accepted for Publication <input type="checkbox"/> Submitted for Publication <input type="checkbox"/> Unpublished and Unsubmitted work written in manuscript style
Publication Details	ANZ J Surg. 2015 Nov;85(11):808-814. Fisher TJ, Osti OL.

Principal Author

Name of Principal Author (Candidate)	Thomas Fisher		
Contribution to the Paper	Entire written component of paper, all data collection & analysis.		
Overall percentage (%)	100%		
Certification:	This paper reports on original research I conducted during the period of my Higher Degree by Research candidature and is not subject to any obligations or contractual agreements with a third party that would constrain its inclusion in this thesis. I am the primary author of this paper.		
Signature		Date	14/3/2017

Co-Author Contributions

By signing the Statement of Authorship, each author certifies that:

- i. the candidate's stated contribution to the publication is accurate (as detailed above);
- ii. permission is granted for the candidate to include the publication in the thesis; and
- iii. the sum of all co-author contributions is equal to 100% less the candidate's stated contribution.

Name of Co-Author	Orso Osti		
Contribution to the Paper	Advice regarding study design, language.		
Signature		Date	14/3/2017

Statement of Authorship

Title of Paper	Modic Changes: Do They Predict Growth of Propionibacterium Acnes in Intervertebral Disc Material?		
Publication Status	<input type="checkbox"/> Published	<input type="checkbox"/> Accepted for Publication	<input checked="" type="checkbox"/> Submitted for Publication
		<input type="checkbox"/> Unpublished and Unsubmitted work written in manuscript style	
Publication Details	Submitted to European Journal of Spine		

Principal Author

Name of Principal Author (Candidate)	Thomas Fisher		
Contribution to the Paper	Entire written component of paper, data analysis. Majority of data collection.		
Overall percentage (%)	90%		
Certification:	This paper reports on original research I conducted during the period of my Higher Degree by Research candidature and is not subject to any obligations or contractual agreements with a third party that would constrain its inclusion in this thesis. I am the primary author of this paper.		
Signature		Date	14/3/2017

Co-Author Contributions

By signing the Statement of Authorship, each author certifies that:

- i. the candidate's stated contribution to the publication is accurate (as detailed above);
- ii. permission is granted for the candidate to include the publication in the thesis; and
- iii. the sum of all co-author contributions is equal to 100% less the candidate's stated contribution.

Name of Co-Author	Orso Osti		
Contribution to the Paper	Advice regarding study design, language. Facilitated & assisted with data collection.		
Signature		Date	14/3/2017

Statement of Authorship

Title of Paper	Modic Changes and Surgical Outcomes		
Publication Status	<input type="checkbox"/> Published	<input type="checkbox"/> Accepted for Publication	<input type="checkbox"/> Unpublished and Unsubmitted work written in manuscript style
	<input checked="" type="checkbox"/> Submitted for Publication		
Publication Details	Submitted to European Journal of Spine		

Principal Author

Name of Principal Author (Candidate)	Thomas Fisher		
Contribution to the Paper	Entire written component of paper, data collection & analysis,		
Overall percentage (%)	100%		
Certification:	This paper reports on original research I conducted during the period of my Higher Degree by Research candidature and is not subject to any obligations or contractual agreements with a third party that would constrain its inclusion in this thesis. I am the primary author of this paper.		
Signature		Date	14/3/2017

Co-Author Contributions

By signing the Statement of Authorship, each author certifies that:

- i. the candidate's stated contribution to the publication is accurate (as detailed above);
- ii. permission is granted for the candidate to include the publication in the thesis; and
- iii. the sum of all co-author contributions is equal to 100% less the candidate's stated contribution.

Name of Co-Author	Orso Osti		
Contribution to the Paper	Advice regarding study design, language. Facilitated data collection.		
Signature		Date	14/3/2017